

EM

# Morning Report

Presented by Dr. S. Yazdani

Supervised by attending physician Dr. M. Naderkhani

# In loving memory of Professor B.Mahshidfar M.D EM Physician



# The patient is

- Male
- 52 y/o
- Iranian
- Non smoker
- Athlete (body building coach )

# C.C

- Stabbing back pain radiating to neck and lower back
- Simultaneously left lower limb went limp

# PMH

- No known PMH
- No medications
- No known allergies

# Present illness

- The symptoms started after an emotional stress and argument at work place
- He felt an stabbing pain in the chest that was radiating to neck and lower back
- At the same time he became hemiplegic at the left lower extremity
- The pain was described as excruciating at first but he was still suffering from chest pain
- No nausea or vomiting

# DDX

- Acute myocardial infarction
- Acute coronary ischemia
- Aortic dissection
- Cardiac tamponade
- Esophageal rupture
- Tension pneumothorax
- Parasagittal tumor /abscess
- Anterior cerebral artery embolism or thrombosis
- Early space-occupying lesions of the spinal cord
- Amyotrophic lateral sclerosis

# On Exam

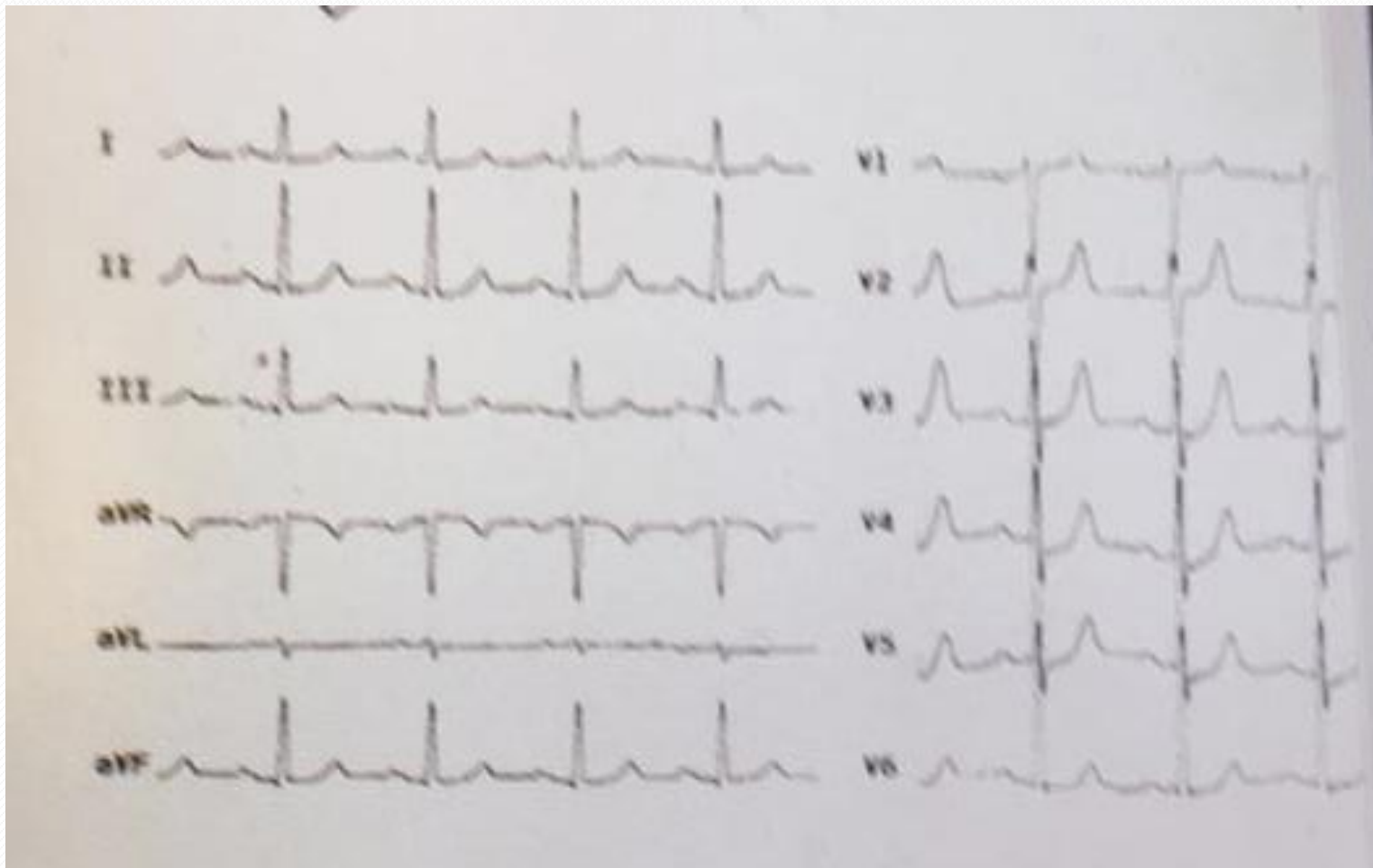
- BP= 167/87 right arm
- BP= 109/64 left arm
- T= 36.8
- PR= 108
- RR=17
- B.S= 169

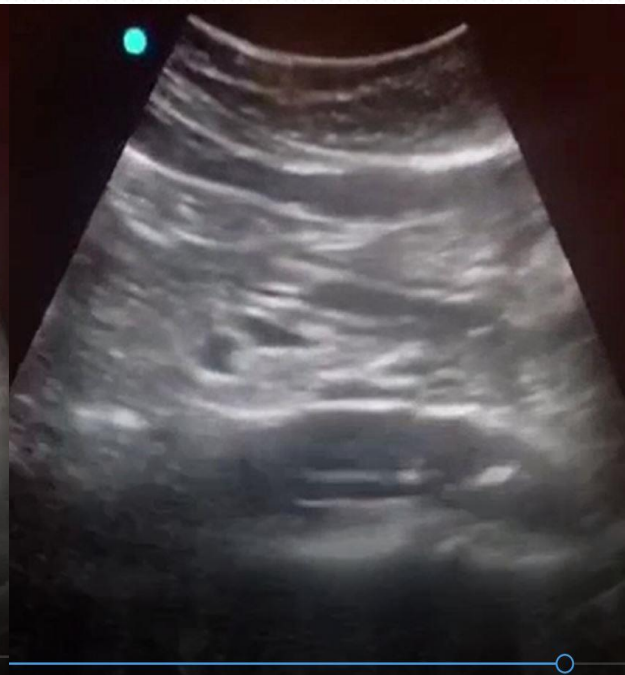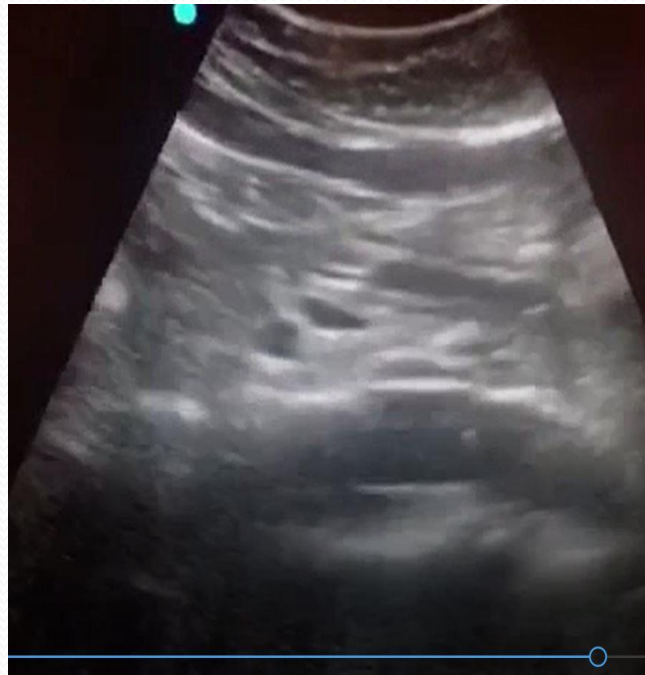
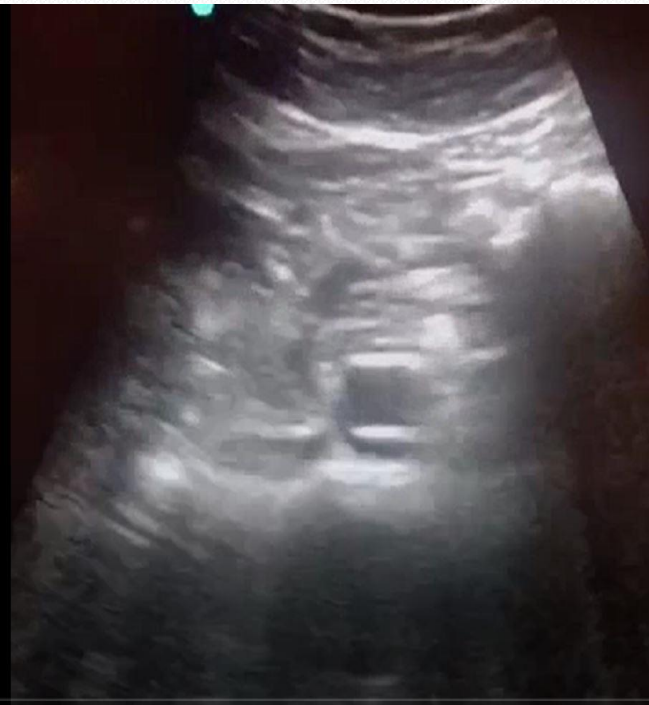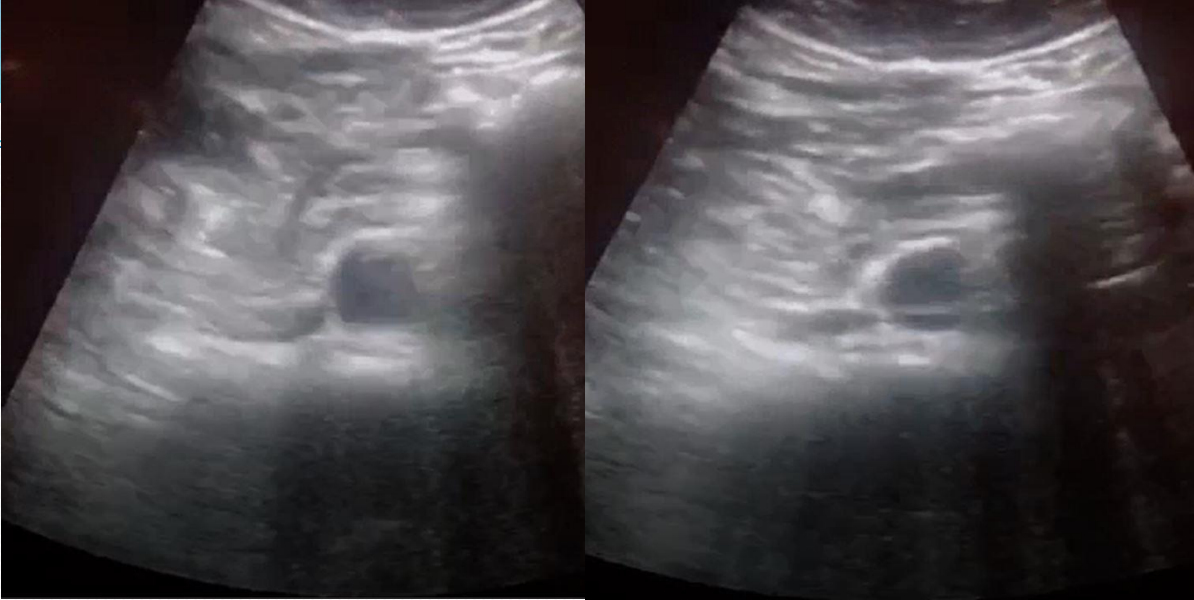


# Positive findings on PH/EX :

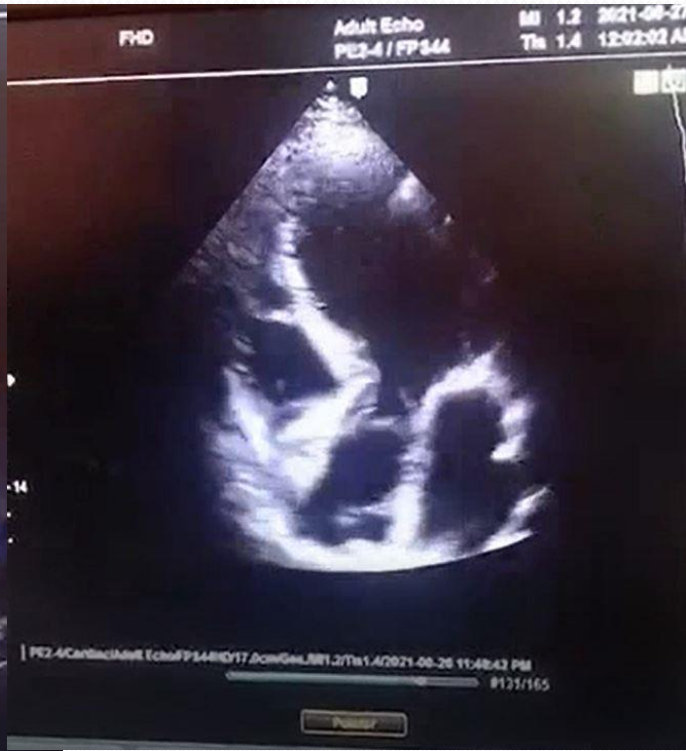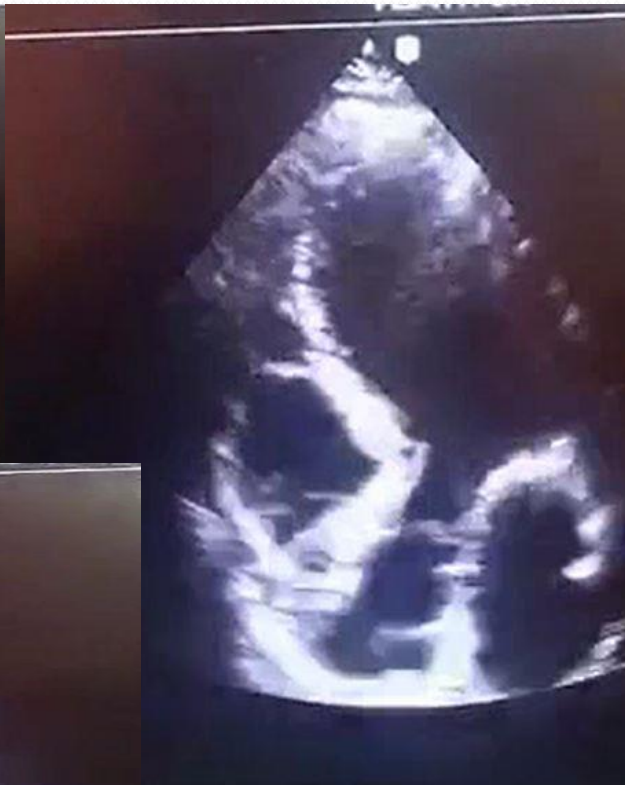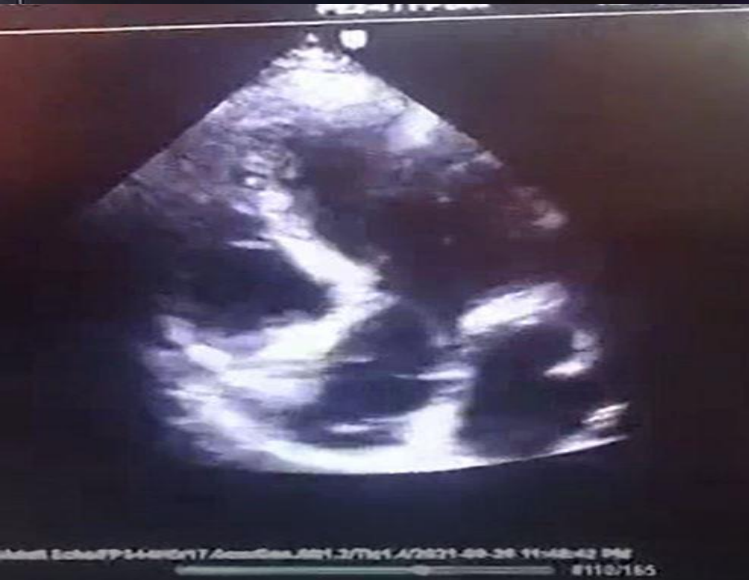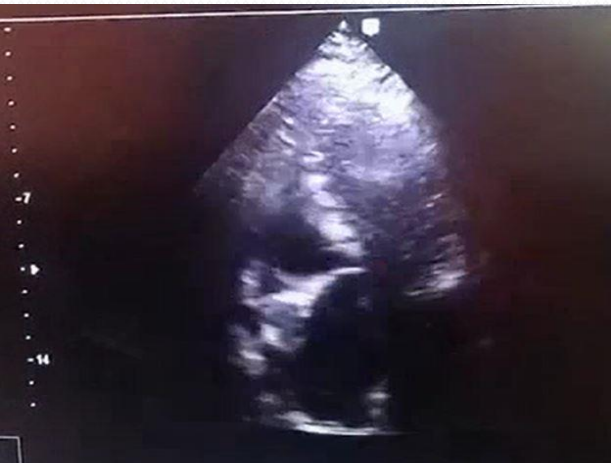- Monoplegia left lower extremity
- Cold left lower extremity
- Pulseless left lower extremity
- No sense of pain below the left knee

# ECG

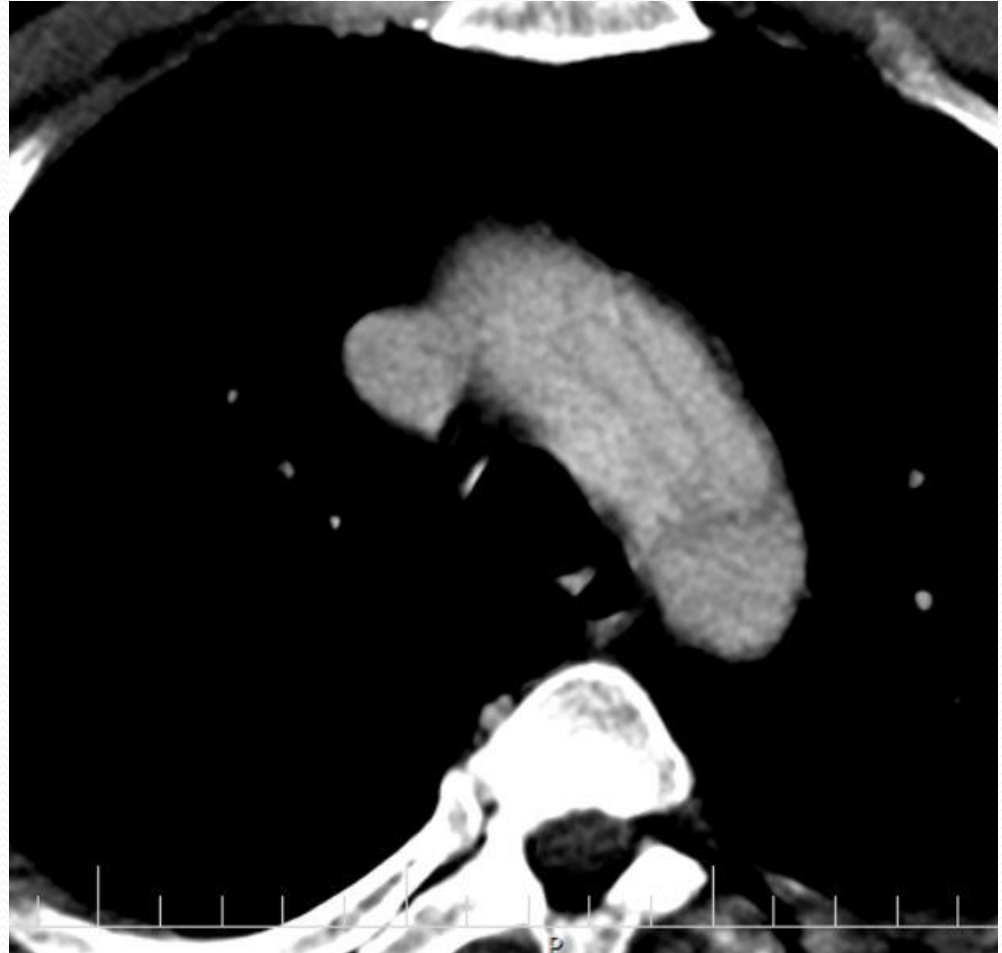
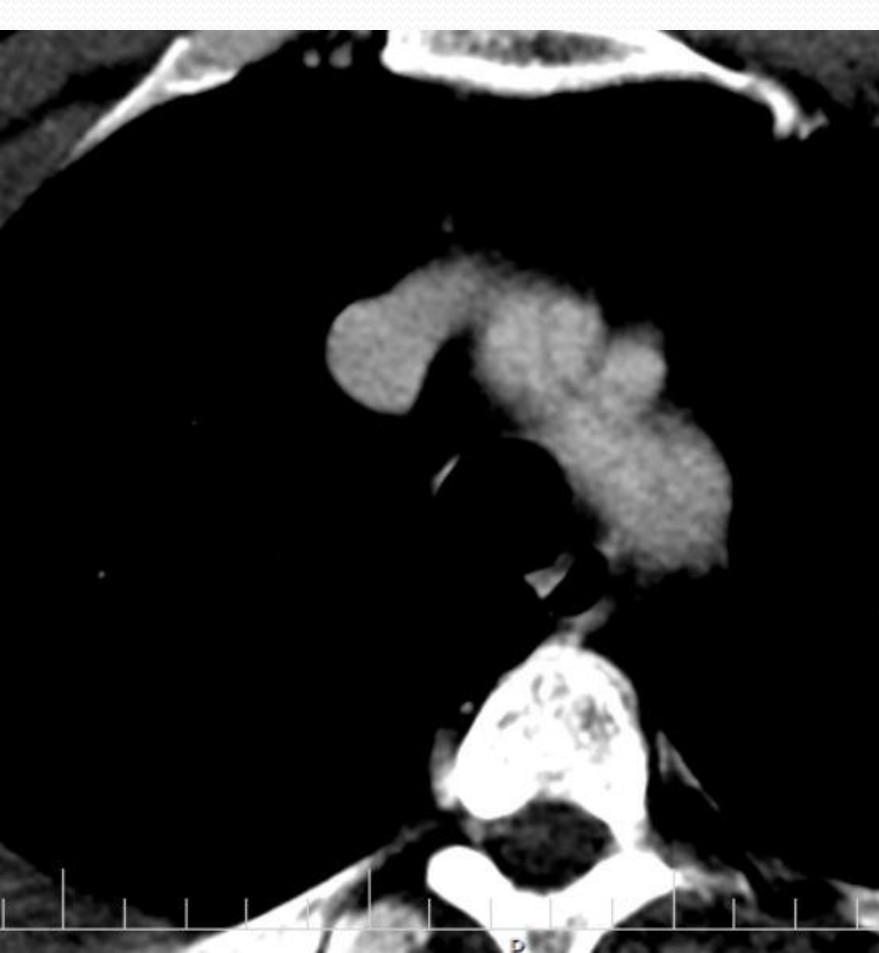



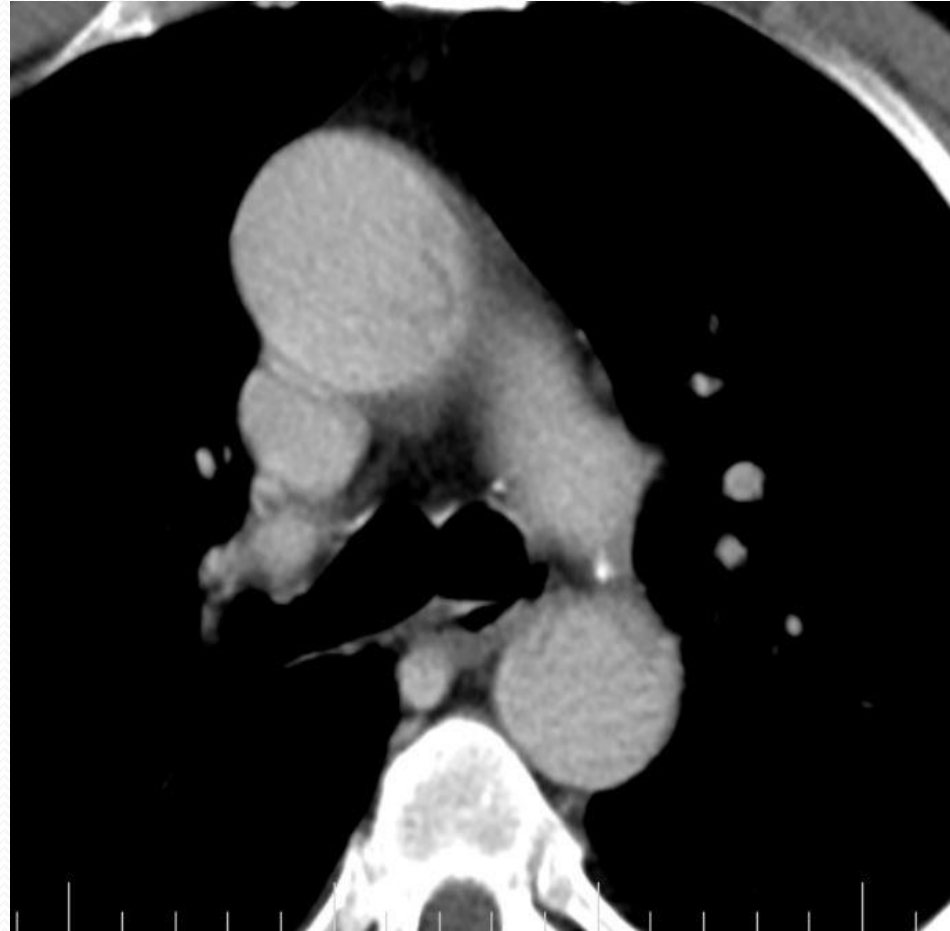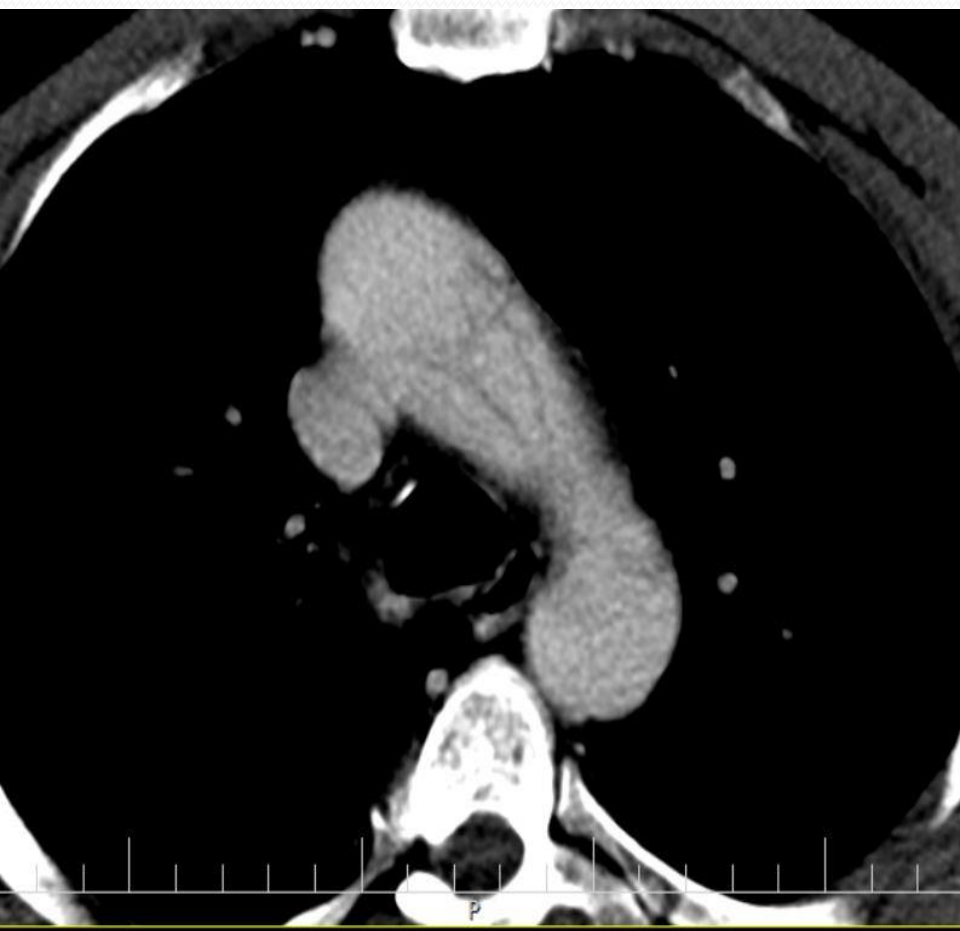
# Bedside echography

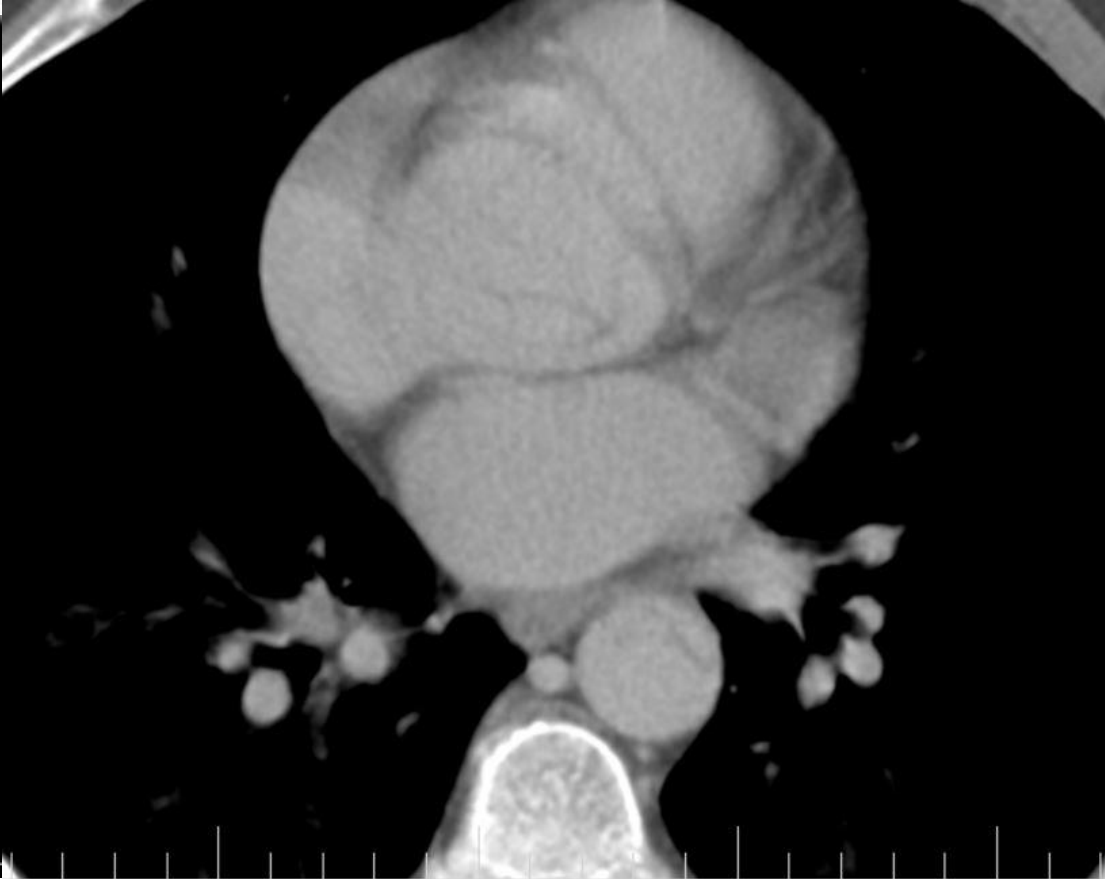
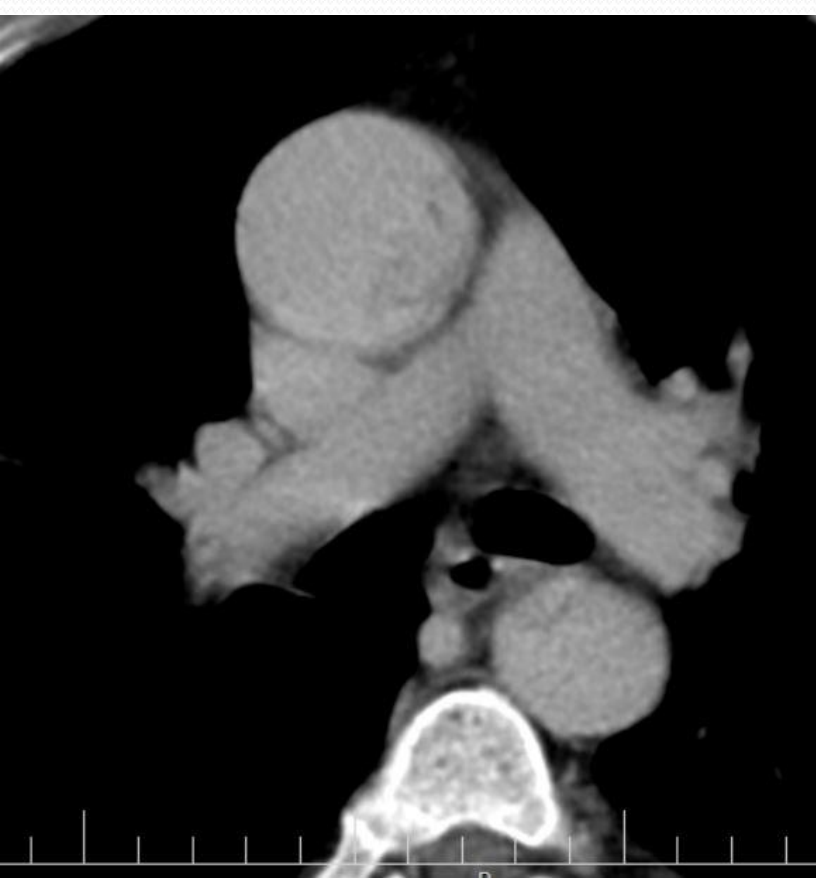
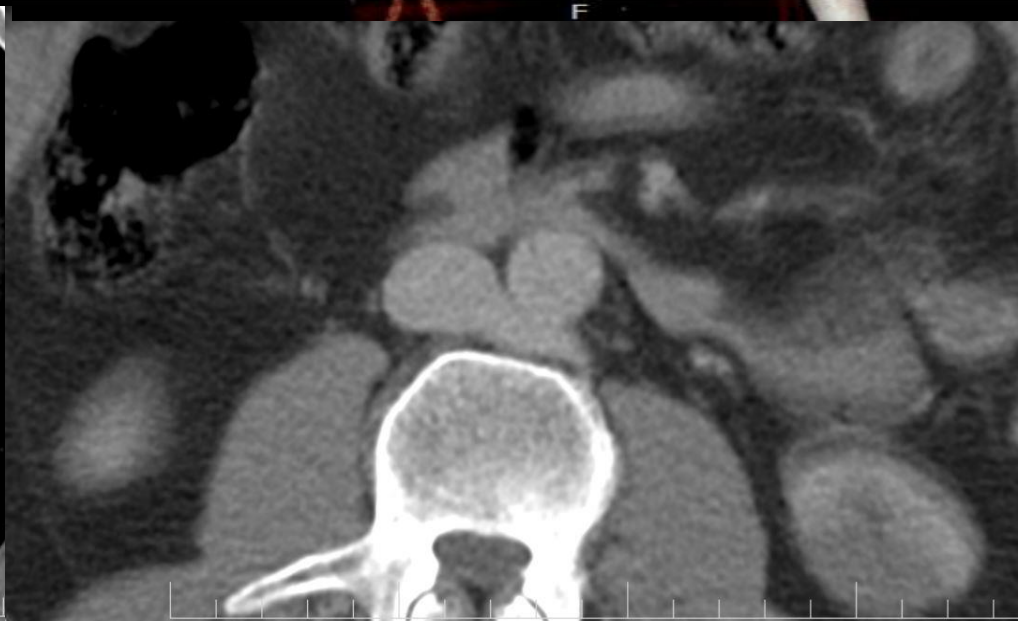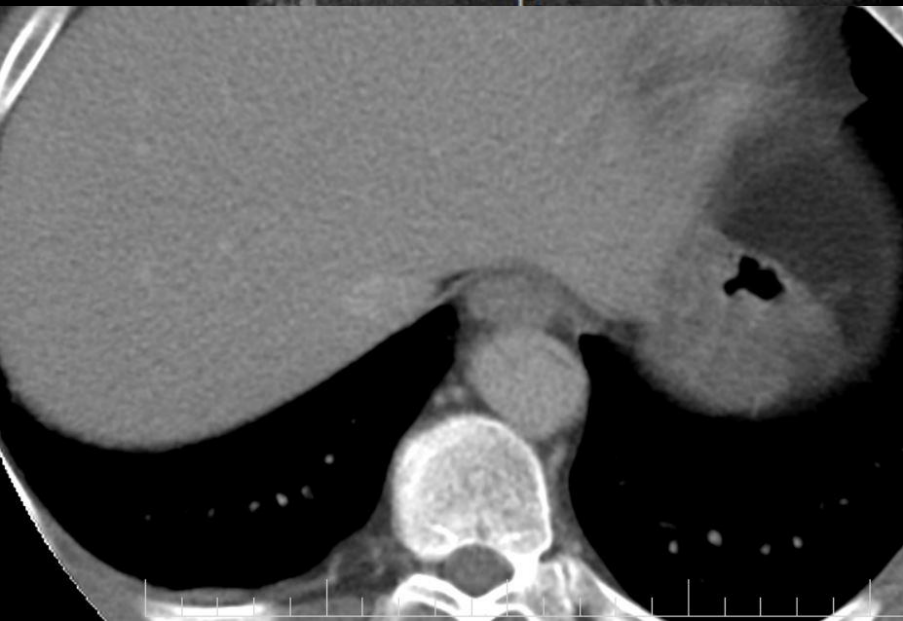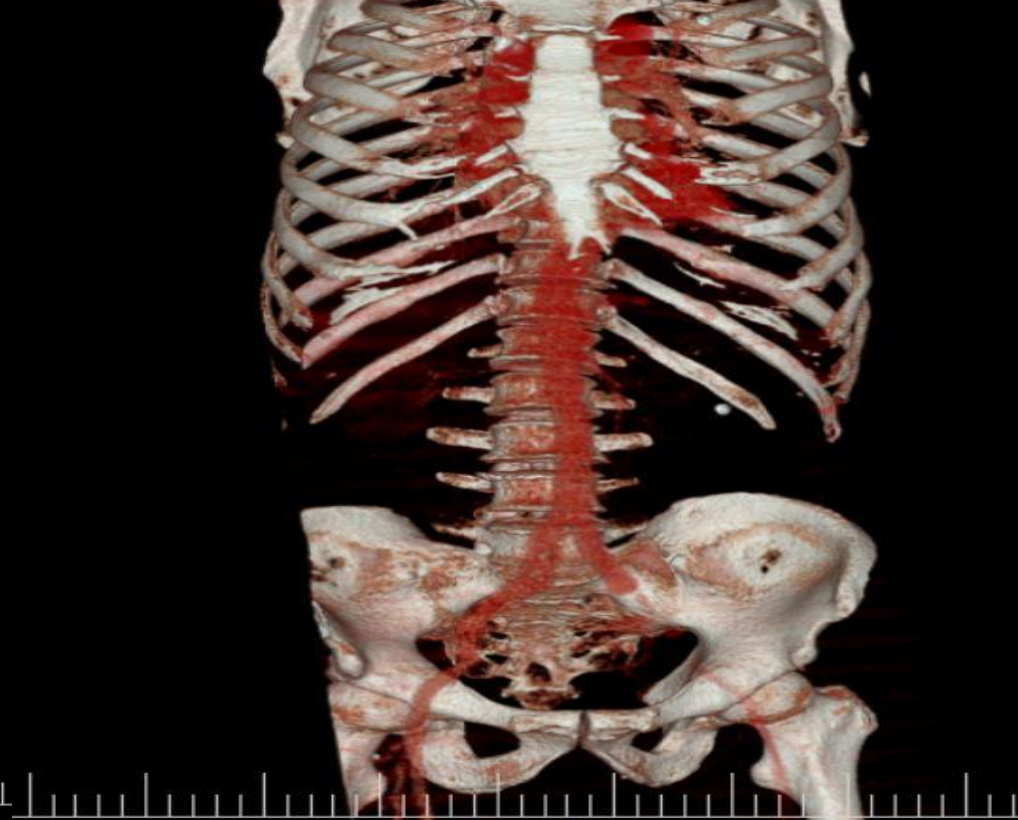
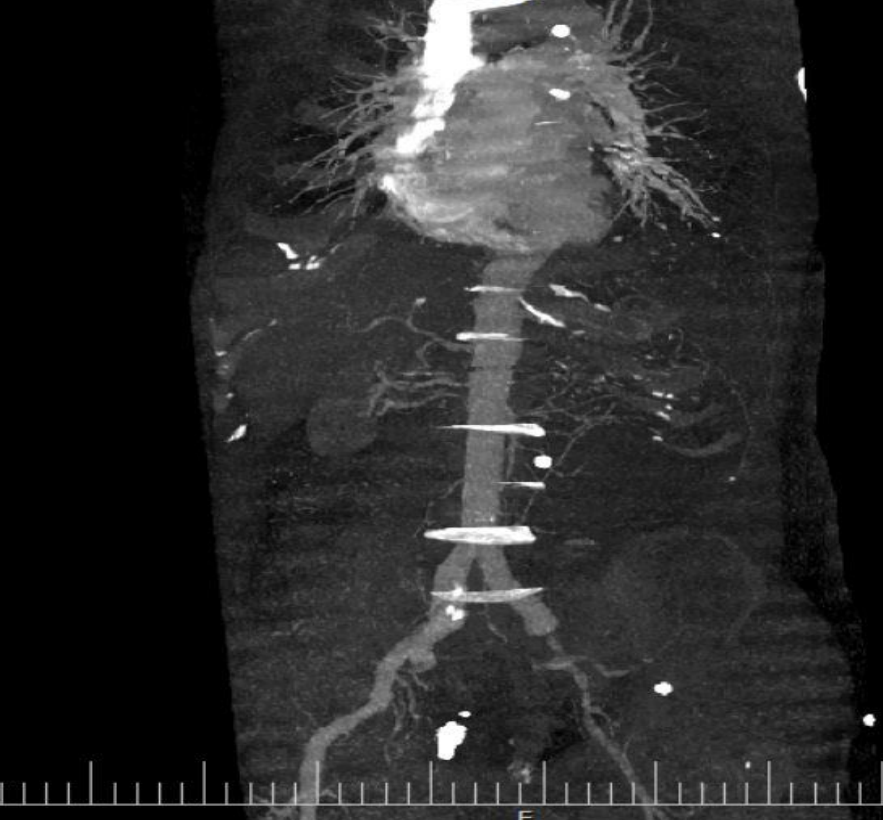# Chest CT angiography













# Lab data

- CBC : WBC 11800 seg 80

HGB 11.9

PLT 187 k

- VBG : Ph 7.32

Pco<sub>2</sub> 43.8

Hco<sub>3</sub> 21.1

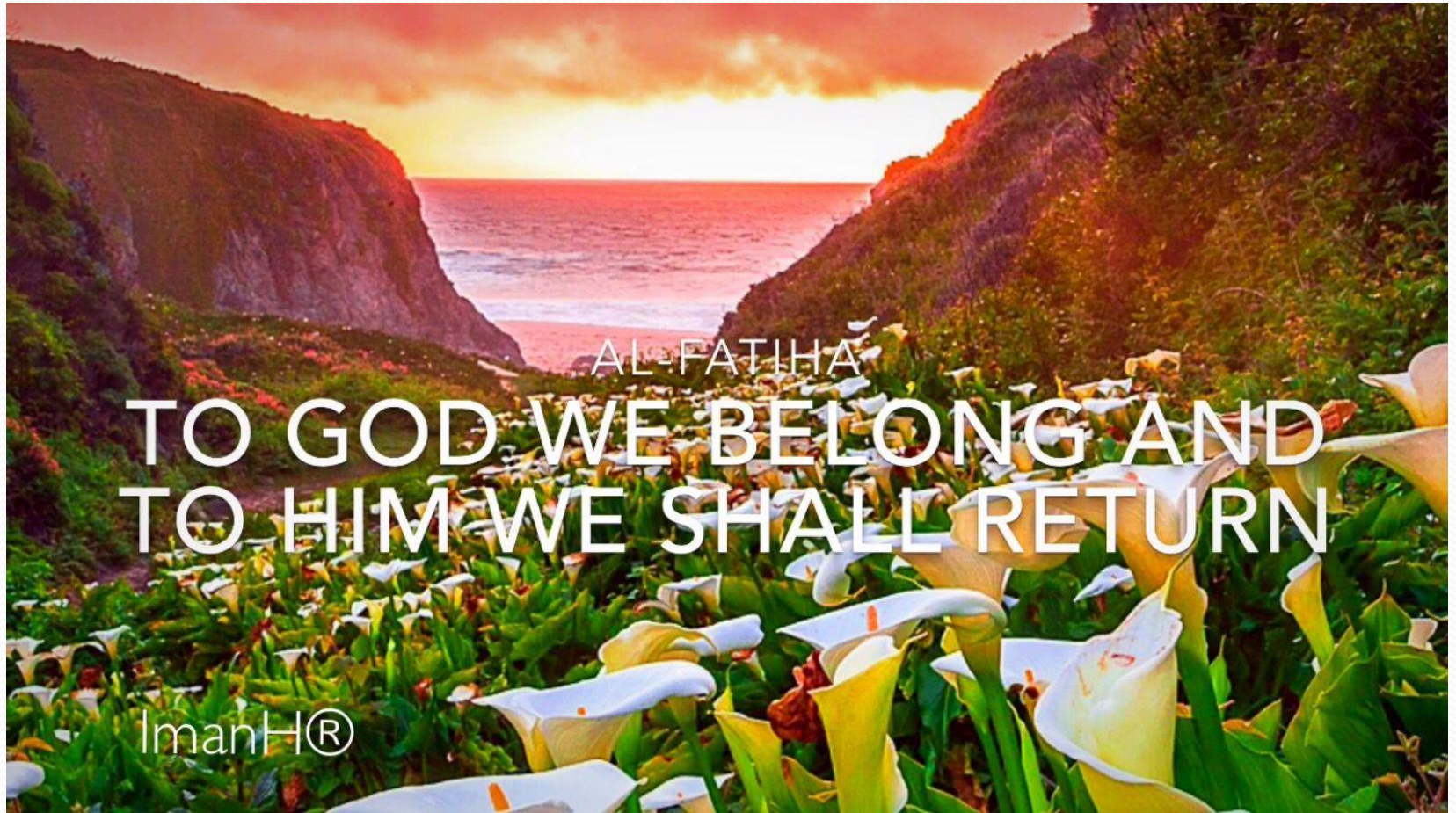- BUN 35 Cr 2.1

- Na 137 K 4.3

# What happened to our patient

- He was transferred to Rasoul as part of Tarh Moein
- Cardiology team at Rasoul carefully examined the patient and felt not confident enough to go through surgery so ;
- It was arranged to Shahid Rejaiee Hos. For the operation at 1:30 am
- He went through operation around 9 am !!
- According to the patient`s son the operation was a success however he was found needing hemodialysis twice
- On the second day after operation he had 2-3 times cardiac arrest which was performed as open chest CPR and the last one was unfortunately not successful .

# الفاتحه



AL-FATIHA  
TO GOD WE BELONG AND  
TO HIM WE SHALL RETURN

ImanH®